PATHOLOGICAL CONDITIONS IN MUSCLE

WESLEY NORMAN

UNIVERSITY OF ILLINOIS
MEDICAL SCHOOL

A dystrophic condition was identified in the longissimus dorsi of porcine animals. Samples of muscle were supplied by Dr. E. J. Briskey of the University of Wisconsin and others were obtained from a slaughterhouse in the Chicago area.

Muscles from two groups of animals were included in the study. The first group consisted of muscles from twenty animals of known breeding and mature age. The second group consisted of 40 muscles of similar weight, but from animals of unknown age and genetic background. In the second group, samples were removed from three levels of the longissimus dorsi; opposite the 5th and 10th thoracic vertebrae and opposite the 2nd lumbar vertebrae. Muscle samples were fixed in formol-calcium, embedded in paraffin, sectioned at 10 microns thickness and stained with hematoxylin and eosin.

In examining fixed tissues for pathological lesions, one must always keep in mind the various artifacts which may occur within a short time following death or those due to the fixation procedure. These artifacts are often manifested in uneven staining properties or a loss of well-defined cell borders. In cross section, the fibers most often shrink so that a space appears between the fiber proper and the cell wall.

Blood vessels appeared essentially normal in all samples observed. A frequent finding was irregular tearing or shredding of the muscle fiber contents. There is still some dispute as to the cause of this process and to its implication in disease of muscle unless other pathological findings are present. The shredding type disruption of fiber contents has been shown to occur following certain fixatives, in muscle during faradic contraction, in frozen muscle upon thawing, in muscle subjected to trauma, and in certain infectious diseases of muscle. Adams, Denny-Brown & Pearson (1962) concluded that necrosis of muscle fibers in the form of irregular clots, with the disruption of fiber contents, was due to extreme contraction of the fiber at the moment of death of the affected fiber. Secondary phenomena were thought to be waxy degeneration.

Waxy or hyaline degeneration was observed in the majority of the samples of group 2. This represents a true degeneration and has been found in infectious diseases (influenza, typhoid fever) as well as some of the muscular dystrophies (nutritional and progressive). The muscle

fiber is swollen along part of its length, striations are known to be preserved in the early lesions but then disappear leaving the fiber as a homogeneous structure. The homogeneous mass then becomes floccular and the necrotic material is later removed by histiocytes. Fig. 1 shows a segment of muscle fiber demonstrating vacuolar degeneration and a centrally located pyknotic nucleus. Regeneration is thought to be more pronounced in this type of degeneration than in the granular type. Although special staining techniques were not used in this study, there were evidences of regeneration associated with this type of degeneration.

Granular degeneration was also observed and has been considered as a disorder of greatest magnitude and more irreversible than waxy degeneration. These lesions have also been observed by other workers around areas of acute focal suppuration, in infections and intoxications. Pyknotic nuclei and nuclear debris are found within the granular material and the final result is invasion of the lesion by histiocytes and lastly by fibroblasts. In many of these areas, all that remains, is a sarcolemmal tube of phagocytes and fiber debris.

Another change, shown in figure 2, which was observed in only three samples, was that of "ringed fibers". These changes occur as a result of aberrant courses taken by myofibrils within abnormal muscle fibers. Some investigators have considered these to be artifacts while others have felt that the lesions have arisen during life. Since most of the affected muscles, in this study, have shown signs of extreme irritability, we felt that when these changes are associated with other degenerative lesions, they may be considered pathological but not indicative of a specific disease entity.

Multiplication of sarcolemmal nuclei has been considered one of the most frequently found changes in degenerative lesions and it is again difficult to assess its value as to a diagnostic process without observing other pathological lesions. These changes were not prevalent in the present investigation. Central displacement of sarcolemmal nuclei into the substance of a muscle fiber is abnormal and was considered to be a pathologic change. Orientation of the centrally displaced nuclei into rows has been thought to be an attempt of the fiber to regenerate. Fig. 3 demonstrates regenerative changes occurring in the small kinked fiber. Large, vesicular, rowed nuclei are centrally located. The nuclei become large and vacuolated with well-defined nuclei. If this is associated with a basaphilia of the sarcoplasm, regeneration is said to be in progress. Nuclear rowing has also been considered as a degenerative change.

Other findings in the porcine longissimus dorsi were an occasional replacement of small groups of fibers by connective or adipose tissue. Such changes are usually found in disease of long duration.

Figure 1.

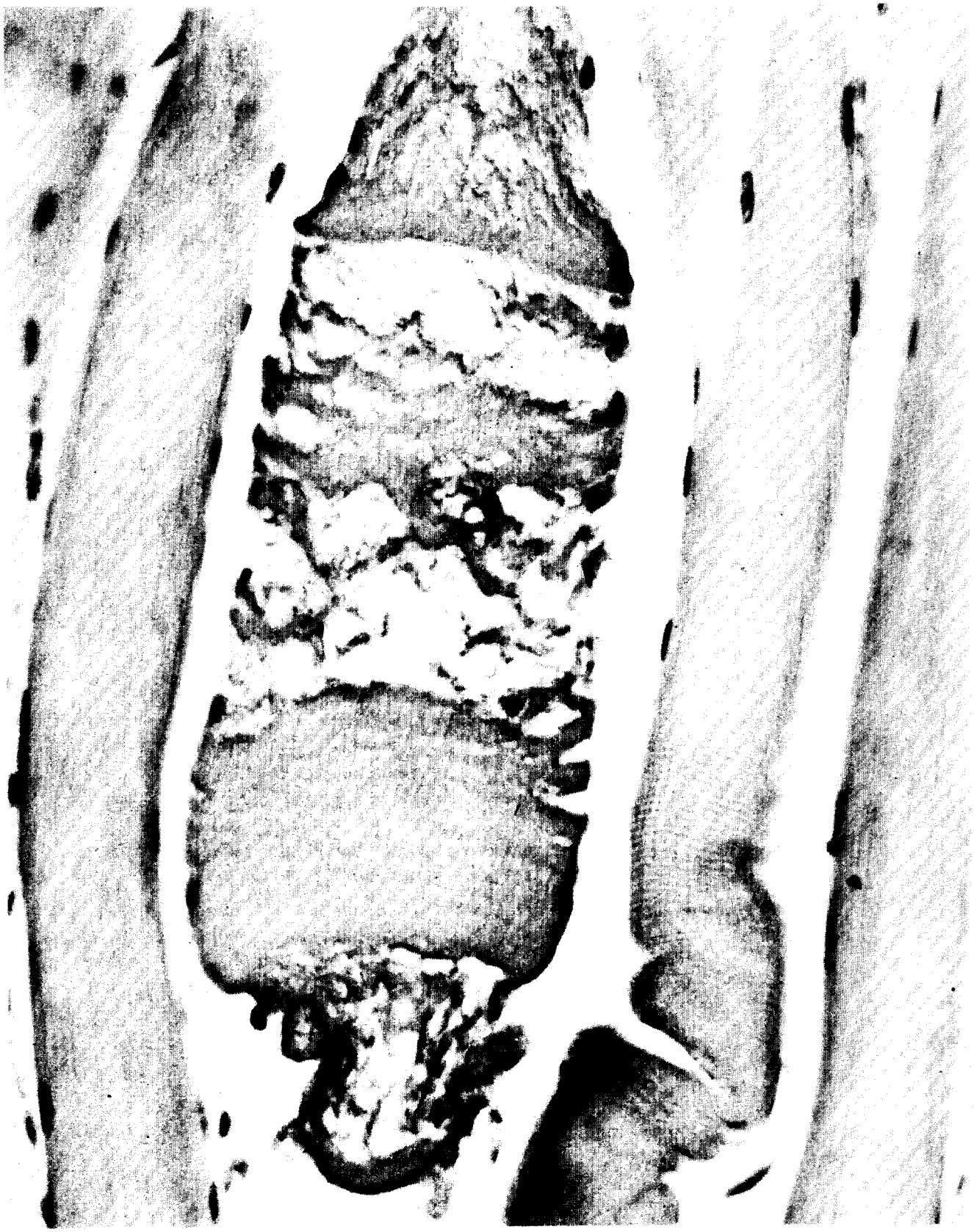

Grossly normal muscle, a segment of muscle fiber demonstrating vacuolar degeneration and a centrally located pyknotic nucleus. x200 H & E.

Figure 2.

PSE Muscle; Ringbinder.

Figure 3.

Grossly normal muscle. The small kinked fiber in the center demonstrates regenerative changes; large vesicular nuclei in a row and centrally located.

R. G. CASSENS: Thank you Mr. Norman for the interesting presentation. We will hold questions for the discussion period to follow the completion of all three papers.

The next speaker is Mr. A. L. Everett from the Hides and Leather Laboratory, U.S.D.A., Eastern Utilization Research and Development Division. He has been trained in microbiology but is now engaged in the histological study of fiber structure. His presentation will describe techniques available for the microscopic study of collagen and other connective tissue components.

# # # # # # # # # # # # #